

Comparison of image quality between flexible coil and special purpose coil sagittal section on mri manus digit 2-3

Alya Verina¹, Hernastiti Sedy Utami², Fani Susanto³, Fathur Rachmat Hidayat⁴, Mochammad Syafi'ie⁵, Alan Samudra⁶

^{1,2,3,4,6}Program Studi Teknologi Radiologi Pencitraan, Fakultas Ilmu Kesehatan, Universitas Muhammadiyah Purwokerto

⁵Instalasi Radiologi RSUP Dr. Sardjito Yogyakarta, Indonesia

ARTICLE INFO

Article history:

Received Apr 9, 2025
Revised Apr 17, 2025
Accepted Apr 23, 2025

Keywords:

Flexible Coil
MRI Manus - α
Special Purpose Coil

ABSTRACT

MRI examination of the manus has a challenge in obtaining optimal image quality. Good image quality depends on four characteristics, one of which is the Signal to Noise Ratio (SNR). SNR can be affected by the use of appropriate radiofrequency (RF) coils so that it can increase the SNR value. This study aims to analyze the impact of using different coils on SNR and CNR values, especially in sagittal sections of Proton Density Fat Sat scans. This study is a quantitative study using 10 volunteer samples in the period of February 2025. The results of the study show that the SNR value in the overall anatomy has a p-value <0.05 which means there is a significant difference using flexible coils and special purpose coils. While the SNR value in per-anatomy manus digits 2-3 has a significant difference except for the volar plate anatomy with a p-value = 0.121 meaning there is no significant difference. And compared to flexible coil, the use of special purpose coil in this study has a higher CNR value, especially in the anatomy of the Distal Interphalangeal Joint - Middle Phalanges with an average value of 1221.200. This study provides evidence that the selection of the right coil greatly affects the quality of the resulting image, and the use of special purpose coil is considered to produce better image quality. Therefore, the author recommends the use of special purpose coils in MRI examinations of the manus digits 2-3.

This is an open access article under the [CC BY-NC](https://creativecommons.org/licenses/by-nc/4.0/) license.



Corresponding Author:

Hernastiti Sedy Utami,
Fakultas Ilmu Kesehatan,
Universitas Muhammadiyah Purwokerto,
Jl. KH. Ahmad Dahlan, Dusun III, Dukuhwaluh, Kec. Kembaran, Kabupaten Banyumas, Jawa Tengah 53182,
Indonesia
Email: hernastitisedyautami@ump.ac.id

INTRODUCTION

Manus the most distal part of the upper limb skeleton consisting of several groups of bones. There are 27 bones in each manus and wrist joint which are divided into three groups, namely 14 phalanges consisting of the fingers and thumbs (Umar & Utama, 2021)(Tinungki et al., 2023). metacarpals which form the palm of the hand and 8 carpals which are the bones of the wrist (John Lampignano, 2018). To evaluate abnormalities or see the anatomy of the manus, an MRI examination can be performed (Meraj, Gyftopoulos, Nellans, Walz, & Brown, 2017).

Magnetic Resonance Imaging (MRI) is a diagnostic imaging modality that does not use ionizing radiation, but instead utilizes the principle of magnetic resonance (Yueniwati, Putri, & Aurora, 2023)(Jatmiko, Wandani, & Istigfarisky, 2021). This technology excels in showing the differences in soft tissue structures in detail, because it can rely on the magnetic properties of the tissue to produce images with better contrast compared to other imaging modalities (Fatimah et al., 2024)(KARTAWIGUNA, nd). The use of MRI on the manus can be done with a fast acquisition time (Johnson & Stevens, 2015).

However, MRI examination is a complex examination technique because the quality of the resulting image is highly dependent on the parameters used. By selecting the right parameters, the resulting image will have optimal quality (Meylisyah, 2022)(Juliantara, Herlina, & Triningsih, 2022).

Good MRI image quality depends on four characteristics, namely Signal to Noise Ratio (SNR), Contrast to Noise Ratio (CNR), scan time and spatial resolution. SNR is the ratio between the magnitude of the signal amplitude and the amplitude of the noise (RANI, 2016)(Salim, 2023). The higher the SNR value, the better the quality of the resulting image. While CNR is the difference between the SNR values on two adjacent networks (Westbrook & Talbot, 2018).

There are several parameters that affect SNR, including Time Repetition (TR), Time Echo (TE), Number of Excitation (NEX), Matrix, Slice Thickness, Bandwidth, Flip Angle and Field of View (FOV). And one of them is the use of radiofrequency (RF) coils (Hidayah, Sutanto, Rudi, & Thohir, 2015). Therefore, the selection of the appropriate radiofrequency (RF) coil is very important to change the direction of the magnetic induction so that the signal can be measured properly in the organ being examined (Arifah, Kartikasari, & Murniati, 2021).

RF coil is designed to detect NMR signals originating from a specific location or object. NMR signals are faint or unclear signals that appear for a short time. These low-power NMR signals can be detected by a carefully designed RF coil and are very sensitive to higher SNR (Anggraini, 2021). These signals can then be converted into visible images through the application of signal and image processing techniques. RF coils are divided into three types, namely receiver coils, transmitter coils and combination receiver - transmitter coils (Wu et al, 2016).

Several types of RF coils used in MRI examinations include surface coils (for example shoulder joint, neck coil and flex/multipurpose coil), volume coils (for example knee coil and head coil) phased array coil (for example body array coil, MR array coil and spine array coil), and quadrature coil (Westbrook & Talbot, 2019). In the protocol and MRI examination technique book created by PARI, MRI examination of the manus is performed using a flex coil.

Flex coil is a type of surface coil that is commonly used in extremity examinations and this coil can increase SNR because this coil is attached to the skin surface of the organ being examined and this coil can be used with certain clinical conditions such as tumors that are quite large, so that the default coil from the examination cannot be used then replaced with a flex coil. In general, the closer the coil is to the surface of the body being examined, the greater the SNR value produced. Surface coils can usually be easily adjusted to the organ being examined with little or no discomfort felt by the patient. This coil is a transceiver coil that functions as a transmitter and receiver (Dutton, 2015).

While special purpose coils are included in the receiver coil without adjustments designed for examinations with a small field of view (Siemens Healthineers). The receiver coil directly affects the quality of the MR signal and also the smaller the coil used, the better the SNR (Westbrook & Talbot, 2019)(Arifah, Kartikasari, & Murniati, 2017).

Based on the description above, it can be seen that a better SNR value can be obtained by determining the right RF coil according to the organ to be examined. And in a preliminary study conducted by the author during PKL at Dr. Sardjito General Hospital Yogyakarta, it was found that the examination of MRI manus used flexible coil and special purpose coil because there was no SOP regarding the use of the two coils. With this finding, the author is interested in conducting a

study aimed at analyzing the impact of using different coils on SNR and CNR values, especially in sagittal sections, because it is more informative in showing joints and ligaments.

RESEARCH METHOD

In this study, quantitative research with an experimental approach was used. The variables used in this study are independent variables, namely flexible coil and special purpose coil and dependent variables referring to the Signal to Noise Ratio (SNR) and Contrast to Noise Ratio (CNR). As well as controlled variables, consisting of Time Repetition (TR), Time Echo (TE), Number of Excitation (NEX), Matrix, Slice Thickness, Bandwidth, Flip Angle, Field of View (FOV) and Region of Interest (ROI). This study was conducted at the Radiology Installation of Dr. Sardjito Hospital Yogyakarta in February 2025, using a Siemens 3 Tesla MRI machine. The number of samples used in this study was 10 volunteers who underwent two MRI scans. Sampling was carried out based on the willingness of volunteers to participate in the study.

Image quality research was conducted by calculating the SNR value on the images of the Distal Interphalangeal Joint (DIP), Middle Phalanges, Proximal Interphalangeal Joint (PIP), Proximal Phalanges, Accessories Collateral Ligament (ACL) and Volar Plate areas. Region of Interest (ROI) in the six anatomies was used to determine the signal value, and the average value of four background points in the object-free area was used to obtain the noise value. The ROI area used was (± 0.02001 cm²) and for DIP and PIP anatomy the ROI placement was (± 0.002001 cm²), then for ACL anatomy the ROI placement was (± 0.0001033 cm²).

After the data was collected, a normality test was performed first. If the data is normally distributed, then it is continued with the Statistic Paired T-Test. However, if the data is not normal, then the Statistic Wilcoxon test is used. H_a is accepted if the p-value <0.05 , indicating a significant difference in the comparison of SNR values between the use of flexible coils and special purpose coils. Conversely, H_a is rejected if the p-value >0.05 , indicating no significant difference in SNR values between the use of flexible coils and special purpose coils in MRI examination of manus digits 2-3. The parameters used in this study are as follows:

Table 1. MRI parameters manus digit 2-3 proton density_TE_FS_sagittal

No.	Parameter	Mark
1.	TR	3800 ms
2.	TE	28 ms
3.	FOV	90mm
4.	Slice Thickness	2mm
5.	Matrix	256 x 256
6.	Flip Angle	160
7.	Bandwidth	181
8.	NEX	2
9.	ROI	0.02001

RESULTS AND DISCUSSIONS

To obtain the standard deviation value and mean signal on the MRI image of the PD_TSE_FS_Sagittal sequence, a Region of Interest (ROI) of (± 0.02001 cm²) was created, for DIP and PIP anatomy the ROI placement was (± 0.002001 cm²), then for ACL anatomy the ROI placement was (± 0.0001033 cm²). The ROI results on the image can be seen in Figure 1.

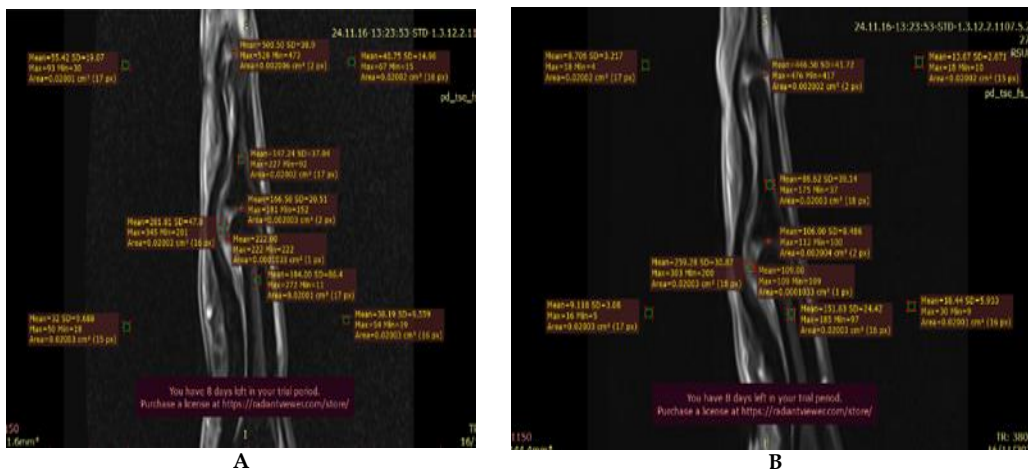


Figure 2. Placement of ROI (A) flexible coil (B) special purpose coil on sample 8

Variations in the use of different coils, namely flexible coils and special purpose coils, show the results of the recapitulation of SNR values in manus anatomy with ROI placement producing different values. The SNR value of manus anatomy using flexible coils is 173.48 and using special purpose coils is 358.15. Based on the results of these calculations, to assess the optimal SNR, a high SNR value of 358.15 can be used. so it can be concluded that the use of special purpose coils is more optimal than using flexible coils in manus examinations which can be seen from the SNR calculation in table 2.

Table 2. Recapitulation results of SNR values on manus digit 2-3 using flexible coil and special purpose coil

Coil	Sample	Anatomical Signal Manus						Noise	Amount	Average SNR
		DIP/N	MP/N	PIP/N	PP/N	ACL/N	VP/N			
Flexible Coil	1	34.58	18.35	35.81	21.35	11.94	6.50	15	128.53	21.42
	2	13.75	8.47	17.07	10.80	5.87	15.68	15.67	71.62	11.94
	3	25.52	5.11	27.55	11.82	10.62	48.36	13.56	125.98	21.50
	4	23.97	11.96	15.36	8.33	7.37	25.88	16.27	92.87	15.48
	5	23.80	4.83	11.07	11.90	5.32	47.28	13.91	104.2	17.36
	6	37.58	11.05	12.50	13.81	16.67	25.49	13.32	117.1	19.52
	7	30.93	10.64	27.70	17.56	18.36	24.08	12.69	129.27	21.54
	8	13.87	2.47	12.80	7.22	2.70	77.01	18.17	116.07	19.34
	9	12.57	6.60	16.69	7.97	7.83	21.64	12.26	73.3	12.22
	10	12.89	6.60	8.44	6.20	5.19	39.64	15.4	78.96	13.16
		Amount								173.48
Special Purpose Coil	1	70.09	17.87	41.88	33.90	8.83	34.04	3.51	206.61	34.43
	2	45.78	22.50	58.74	19.55	30.81	50.47	3.83	227.85	37.97
	3	70.00	11.37	34.49	13.80	12.52	45.75	5,031	187.93	31.64
	4	55.71	11.56	16.76	4.50	23.75	55.64	4,506	167.92	27.99
	5	75.79	17.93	47.94	20.80	16.63	44.37	3,609	223.46	37.24
	6	118.27	22.94	28.08	40.16	28.87	68.68	3,775	307	51.16
	7	40.00	13.94	53.08	26.57	51.49	68.64	3,787	253.72	42.29
	8	62.89	5.17	31.77	5.50	35.26	30.90	4,595	171.49	28.58
	9	90.00	12.05	23.44	10.91	20.37	23.04	5,056	179.81	29.97
	10	39.78	22.30	27.59	8.77	61.46	61.34	4,7835	221.24	36.87
		Amount								358.15

Test Results Using SPSS

Table 3. Normality test, SNR data anatomy of manus digit 2-3 overall using flexible coil and special purpose coil

	Tests of Normality					
	Kolmogorov-Smirnova			Shapiro Wilk		
	Statistics	df	Sig.	Statistics	df	Sig.
Flexible Coil	.122	60	.000	.815	60	$p < 0.001$
Special Purpose Coil	.170	60	.027	.925	60	0.001

Based on table 3. It is known that the results of the data normality test with the flexible coil asymp.Sig value are $p < 0.001$ ($p < 0.05$) and the special purpose coil asymp.Sig value is 0.001 ($p < 0.05$), which indicates that the data is not normally distributed. Because the data is not normally distributed, it is continued with the Wilcoxon test.

Table 4. Wilcoxon test, anatomical SNR data for manus digits 2-3 overall using flexible coil and special purpose coil

Coil	Mean Rank	Signification (p-value)
Flexible Coil	13.63	$p < 0.001$
Special Purpose Coil	33.10	

In table 4 the results of the Wilcoxon test using calculation software with sig. values show the results of the hypothesis decision. The results of the Wilcoxon calculation show that H_0 is rejected and H_a is accepted, with $p < 0.001$ ($p < 0.05$). The results show that there is a difference in image quality between human anatomy in the SNR aspect using flexible coils and special purpose coils.

Table 5. Normality test, SNR data per-anatomy manus digit 2-3 using flexible coil and special purpose coil

Variables	Anatomy	pvalue/sig	Meaning
SNR Flexible Coil	Distal Interphalangeal Joint	0.361	Normal
	Middle Phalanges	0.369	Normal
	Proximal Interphalangeal Joint	0.790	Normal
	Proximal Phalanges	0.481	Normal
	Accessories Collateral Ligaments	0.424	Normal
	Volar Plate	0.699	Normal
SNR Special Purpose Coil	Distal Interphalangeal Joint	0.159	Normal
	Middle Phalanges	0.536	Normal
	Proximal Interphalangeal Joint	0.142	Normal
	Proximal Phalanges	0.334	Normal
	Accessories Collateral Ligaments	0.313	Normal
	Volar Plate	0.351	Normal

Table 5 shows the significance value of SNR on MRI manus using flexible coil and special purpose coil $p > 0.05$, so it can be concluded that the data is normally distributed. Because the data is normally distributed, it is continued with the Paired T-Test statistical test.

Table 6. Paired t-test statistical test results, SNR data per-anatomy manus digit 2-3 using flexible coil and special purpose coil

Variables	Anatomy	p value/sig	Meaning
SNR Flexible Coil and SNR Special Purpose Coil	Distal Interphalangeal Joint	$p < 0.001$	There is a Difference
	Middle Phalanges	0.005	There is a Difference
	Proximal Interphalangeal Joint	0.002	There is a Difference
Special Purpose Coil	Proximal Phalanges	0.035	There is a difference
	Accessories Collateral Ligaments	0.006	There is a Difference
	Volar Plate	0.121	There is no difference

From table 6 it can be seen that there are differences in 5 anatomies with the description of Distal Interphalangeal Joint with $p < 0.001$, Middle Phalanges with $p\text{-value} = 0.005$, Proximal Interphalangeal Joint with $p\text{-value} = 0.002$, Proximal Phalanges with $p\text{-value} = 0.035$, Accessories Collateral Ligamen with $p\text{-value} = 0.006$ and for the anatomy of Volar Plate with $p\text{-value} = 0.121$ has the meaning there is no difference.

After the SNR value is obtained, the CNR value is recorded by finding the difference between the SNR values of the two adjacent anatomies as in table 6.

Table 7. CNR value measurement results for anatomical manus digits 2-3

Coil	Sample	DIP - MP	PIP - PP	VP - ACL
Flexible Coil	1	1.08	0.96	0.36
	2	0.34	0.40	0.63
	3	1.51	1.16	2.78
	4	0.74	0.43	1.14
	5	1.36	0.06	3.02
	6	1.99	0.10	0.66
	7	1.60	0.80	0.45
	8	0.63	0.31	4.09
	9	0.49	0.71	1.13
	10	0.41	0.15	2.24
Special Purpose Coil	1	14.87	2.27	7.18
	2	11.34	10.23	5.13
	3	7.58	4.11	6.61
	4	9.80	2.72	7.08
	5	16.03	7.52	7.69
	6	25.25	3.20	10.54
	7	12.64	7.00	4.53
	8	12.56	5.72	0.95
	9	10.66	2.48	0.53
	10	10.72	3.94	0.03

Table 8. Test results difference, CNR data anatomy manus digit 2-3

Anatomy		Average value	p-value
Distal Interphalangeal Joint - Middle Phalanges	Flexible Coil	101,500	$p < 0.001$
	Special Purpose Coil	1221,200	
Proximal Interphalangeal Joint - Proximal Phalanges	Flexible Coil	50,800	0.001
	Special Purpose Coil	491,900	
Accessories Collateral Ligament - Volar Plate	Flexible Coil	165,000	0.001
	Special Purpose Coil	502,700	

In the analysis of CNR value is set with a level of significance with a value of 0.05. CNR value data can be said that there is a significant difference between the use of flexible coil and special purpose coil in the anatomy of the Distal Interphalangeal Joint - Middle Phalanges $p\text{-value} < 0.001$, anatomy of the Proximal Interphalangeal Joint - Proximal Phalanges $p\text{-value} = 0.001$ and anatomy of Accessories Collateral Ligamen - Volar Plate $p\text{-value} = 0.001$, ($p\text{-value} < 0.05$), so it means there is a significant difference between the use of flexible coil and special purpose coil.

The results of the Paired T-Test showed that the average CNR value for the Distal Interphalangeal Joint - Middle Phalanges anatomy was 1221.200 higher when using a special purpose coil than using a flexible coil, the average CNR value for the Proximal Interphalangeal Joint - Proximal Phalanges anatomy was 491.900 higher when using a special purpose coil than using a flexible coil and the Accessories Collateral Ligament - Volar Plate anatomy was 502.700 higher when using a special purpose coil than using a flexible coil.

Discussion

Based on the results of the study using 10 samples regarding the evaluation of the Signal to Noise Ratio (SNR) and Contrast to Noise Ratio (CNR) values in MRI examination of the manus using flexible coils and special purpose coils with a Siemens 3 Tesla MRI machine at the Radiology Installation of Dr. Sardjito General Hospital Yogyakarta, it can be explained as follows:

- a. The Use of Flexible Coil with Special Purpose Coil in MRI Examination of Manus Digit 2-3 Has Different Anatomical Image Quality.

The study findings show that the use of two coils in MRI examination of the manus between flexible coil and special purpose coil significantly affects image quality (SNR). The mean SNR value in this study was higher when a special purpose coil was used than when using a flexible coil. Only the volar plate anatomy did not show a significant difference after testing on the six anatomies. The results of this study are in line with the findings of previous studies which showed that the use of a special purpose coil produced a higher SNR value compared to the use of a conventional coil (Su et al., 2020). This advantage can be explained by the special design of the special purpose coil, which is designed for examination with a small Field of View (FOV) such as in the manus digit 2-3 area. This design allows the special purpose coil to maximize signal capture in a more specific area, while reducing noise interference that often occurs in conventional coils. Thus, the use of special purpose coils can significantly improve image quality and provide higher resolution. This study is also in line with the findings expressed by (Ringler & Murthy, 2015), which states that the use of coils with smaller diameters can increase the SNR value and contrast ratio. However, the use of coils with this size also limits the FOV that can be covered. This is evident from the use of special purpose coils in MRI examinations of manus digits 2-3 which produced high mean SNR values as evidenced by the Wilcoxon difference test with an average SNR value of special purpose coils of 33.10 while the average SNR value of flexible coils was 13.63. The results of this study indicate that the use of flexible coils with special purpose coils significantly affects image quality (SNR). Compared with flexible coils, the use of special purpose coils in this study has a higher CNR value. Anatomy of the Distal Interphalangeal Joint - Middle Phalanges obtained the highest value after testing on two different anatomies. In line with the theory (Westbrook & Talbot, 2019) that the boundary between one anatomy and another is very clear if the CNR on the anatomy has a high value, the findings of this study indicate that the anatomical boundaries are more clearly visible when a special purpose coil is used, as shown in Table 8, where a high CNR value was recorded. This increase in CNR makes it easier to distinguish between anatomical and pathological areas, thus facilitating image identification and interpretation.

In this study, the sequence used in the MRI examination of manus digit 2-3 namely PD FatSat, FatSat technique plays an important role in increasing the CNR value because of its ability to suppress signals from fat. This produces high-resolution images. In addition, the use of PD weighting is also effective in evaluating low-quality structures, such as ligaments and bone or tissue structures. This finding is in line with research conducted (Mulyati et al., 2019) with the use of special purpose coils on MRI examination of manus digits 2-3 with the PD_TSE_FS_Sagittal sequence produced a high average CNR value as evidenced by the Paired T-Test difference test with an average CNR value of special purpose coils of 1221,200 (DIP-MP), 491,900 (PIP-PP) and 502,700 (ACL-VP). While the average CNR value of flexible coils is 101,500 (DIP-MP), 50,800 (PIP-PP), and 165,000 (ACL-VP).

- b. Coils that are more optimal in showing the quality of anatomical images in MRI examinations of the Manus Digits 2-3 using Flexible Coils and Special Purpose Coils.

In the MRI examination of the manus using flexible coil and special purpose coil, the average SNR value was obtained for each coil of 33.10 and 13.63, which means that the average SNR value of the special purpose coil is higher than the flexible coil. This is in accordance with previous research which stated that the special purpose coil is part of the receiver coil, which has an important role in improving image quality in MRI imaging techniques. The study revealed that

a receiver coil with a small dimension, such as a special purpose coil, can provide a significant increase in SNR compared to a conventional coil with a larger dimension.(Volland, Kholmovski, Parker, & Hadley, 2013). This increase in SNR not only improves image quality, but also improves the resolution and sharpness of detail in the resulting image. One of the main advantages of using a small receiver coil is its ability to allow a reduction in the field of view (FOV) of the image. With this reduction, irrelevant areas in the image can be minimized, allowing for increased focus on the areas of primary interest. The use of coils with smaller diameters can also improve patient comfort because they are easier to position and take up less space in the scanner. Therefore, the application of special purpose coils in MRI can be expected to provide great benefits, both in terms of image quality and the efficiency of the imaging procedure itself.

CONCLUSION

In this study, the use of special purpose coils showed more optimal results in producing image quality compared to flexible coils in MRI examination of manus digits 2-3. Special purpose coils are specifically designed to provide higher resolution and increase contrast in certain areas of the body, such as hands and fingers, which can affect diagnostic accuracy. Meanwhile, flexible coils, despite their flexibility and ease of use, have been shown to be unable to provide details as sharp and clear as those produced by special purpose coils, especially in MRI examinations of small areas with complex structures such as manus digits 2-3.

This study provides evidence that the selection of the right coil greatly affects the quality of the resulting image, and the use of special purpose coils is considered to produce better image quality. Therefore, the author recommends the use of special purpose coils in MRI examination of manus digits 2-3.

ACKNOWLEDGEMENTS

The author would like to thank RSUP Dr. Sardjito Yogyakarta for granting permission in the research process. The supervisor who has provided direction so that the author can complete this scientific article to completion, friends and all parties who have helped and guided in making this research.

References

- Anggraini, D. T. (2021). Analisis Dukungan Suami dan Perilaku Ibu Nifas Dalam menggunakan KB Pasca Persalinan di Kecamatan Kisaran Barat Kabupaten Asahan. Universitas Islam Negeri Sumatera Utara.
- Arifah, A. N., Kartikasari, Y., & Murniati, E. (2017). Analisis Perbandingan Nilai Signal to Noise Ratio (SNR) pada Pemeriksaan MRI Ankle Joint dengan Menggunakan Quad Knee Coil dan Flex/Multipurpose Coil. *Jurnal Imejing Diagnostik (JImeD)*, 3(1), 220-224.
- Arifah, A. N., Kartikasari, Y., & Murniati, E. (2021). Comparative Analysis of the Value of Signal To Noise Ratio (Snr) At Mri Ankle Joint Examination Using Quad Knee Coil and Flex/Multipurpose Coil. *JImeD*, 3(1), 220-224.
- Dutton, M. (2015). *Dutton's Orthopaedic Examination, Evaluation, and Intervention*.
- Fatimah, S., binti Ismail, N. F., Masrochah, S., Dartini, S. K. M., Darmini, S. S., Aryani, A. I., & binti Ali, A. (2024). *PENCITRAAN DIAGNOSTIK WANITA: PRINSIP, PATOLOGI UMUM DAN MODALITAS IMEJING*. Cendikia Mulia Mandiri.
- Hidayah, S., Sutanto, H., Rudi, D., & Thohir, S. (2015). Pengaruh Perubahan Tr Terhadap Nilai Cnr Dan Efisiensi Kontras Pada Citra Mri Head Sequence T1 Weighted Image. *Youngster Physics Journal*, 4(1), 93-98.
- Jatmiko, A. W., Wandani, C. A., & Istigfarisky, L. W. (2021). Efek Pemakaian Kontras Untuk Optimalisasi Citra Pada Pemeriksaan Diagnostik Magnetic Resonance Imaging (MRI). *Jurnal Biosains Pascasarjana*, 23(1), 28.
- John Lampignano, L. K. (2018). *Textbook of Radiographic Positioning and Related Anatomy*.

- Johnson, D., & Stevens, K. J. (2015). A p p r o a c h t o M R I m a g i n g o f t h e E l b o w a n d W r i s t Technical Aspects and Innovation, 94305.
- Juliantara, I. P. E., Herlina, W., & Triningsih, T. (2022). Optimalisasi Citra Mri Wrist Joint Dengan Penerapan 3D Isotropik Pada Pembobotan Proton Density Di Instalasi Radiologi Rsup Dr. M. Djamil Padang. *Jurnal Syntax Admiration*, 3(12), 1601-1611. <https://doi.org/10.46799/jsa.v3i12.537>
- KARTAWIGUNA, D. (n.d.). PENGANTAR PENCITRAAN MEDIS.
- Meraj, S., Gyftopoulos, S., Nellans, K., Walz, D., & Brown, M. S. (2017). MRI of the extensor tendons of the wrist. *American Journal of Roentgenology*, 209(5), 1093-1102. <https://doi.org/10.2214/AJR.17.17791>
- Meylisyah, A. (2022). PENGGUNAAN ARANG AKTIF TEMPURUNG SIWALAN SEBAGAI MEDIA FILTRASI DALAM MENURUNKAN KESADAHAN AIR DI DESA LANCA KABUPATEN BONE= USE OF ACTIVE CHARCOAL OF SIWALAN TEMPURUNG AS FILTRATION MEDIA IN REDUCING WATER HARDNESS in LANCA VILLAGE, BONE REGENCY. Universitas Hasanuddin.
- Mulyati, S., Rusyadi, L., Rahmawati, I. M. P., Fatimah, Wibowo, A. S., Indrati, R., & Rasyid. (2019). Differentiation Image Quality of MRI Shoulder Joint with Variation RF Coils. *E3S Web of Conferences*, 125(201 9), 7-11. <https://doi.org/10.1051/e3sconf/201912518001>
- RANI, D. E. G. A. (2016). Optimalisasi Number Of Excitation (Nex) Terhadap Signal To-Noise Ratio (Snr) Dan Kecepatan Waktu Scanning Pada Pemeriksaan MRI. Universitas Airlangga.
- Ringler, M. D., & Murthy, N. S. (2015). MR Imaging of Wrist Ligaments. *Magnetic Resonance Imaging Clinics of North America*, 23(3), 367-391. <https://doi.org/10.1016/j.mric.2015.04.007>
- Salim, A. (2023). ANALISIS NILAI SNR DAN CNR PHANTOM HASIL PEMERIKSAAN CT-SCAN DENGAN METODE AXIAL DAN HELICAL DI RS HAJI MAKASSAR. Universitas Hasanuddin.
- Su, T., Chen, Y., Zhang, Z., Zhu, J., Liu, W., Chen, X., ... Jin, Z. (2020). Optimization of Simultaneous Multislice, Readout-Segmented Echo Planar Imaging for Accelerated Diffusion-Weighted Imaging of the Head and Neck: A Preliminary Study. *Academic Radiology*, 27(11), e245-e253. <https://doi.org/10.1016/j.acra.2019.12.008>
- Tinungki, Y. L., Hairat, U., Rinarto, N. D., Supatmi, S., Destari, P. L., Zen, S., ... Erawati, N. K. (2023). *Buku Ajar Ilmu Biomedik Dasar*. PT. Sonpedia Publishing Indonesia.
- Umar, M. S., & Utama, J. P. (2021). *Anatomi Tubuh Manusia*. Samudra Biru.
- Volland, N. A., Kholmovski, E. G., Parker, D. L., & Hadley, J. R. (2013). Initial feasibility testing of limited field of view magnetic resonance thermometry using a local cardiac radiofrequency coil. *Magnetic Resonance in Medicine*, 70(4), 994-1004. <https://doi.org/10.1002/mrm.24534>
- Westbrook, C., & Talbot, J. (2018). *Handbook of MRI Technique-Wiley-Blackwell. Analytical Biochemistry* (Vol. 11).
- Westbrook, C., & Talbot, J. (2019). *MRI in Practice. Sustainability (Switzerland)* (Vol. 11).
- Xiaoping Wu, Xiaotong Zhang, Jinfeng Tian, Sebastian Schmitter, Brian Hanna, John Strupp, Josef Pfeuffer, Michael Hamm, Dingxin Wang, Juegen Nistler, Bin He J, Thomas Vaughan, Kamil Ugurbil, and P.-F. V. de M. (2016). Comparison of radiofrequency body coils for MRI at 3 Tesla: a simulation study using parallel transmission on various anatomical targets. *Physiology & Behavior*, 176(1), 139-148. <https://doi.org/10.1002/nbm.3378.Comparison>
- Yueniwati, Y., Putri, S. L., & Aurora, H. (2023). *Magnetic Resonance Spectroscopy pada Otak: Prinsip dan Aplikasi Klinis*. Universitas Brawijaya Press.