

Extraction of Foreign Body Aspiration in Children

Nisa Haska Maulina¹, Finny Fitry Yani²

¹Resident of Pediatric of Medical Faculty, Universitas Andalas, Padang, Indonesia

²Lecture of Pediatric Respirologist of Medical Faculty, Universitas Andalas, Padang, Indonesia

ARTICLE INFO

Keywords:

Foreign body aspiration, Bronchoscopy

E-mail:

Finny_fy@yahoo.com

ABSTRACT

Aspiration of foreign bodies by children can lead to serious illness and sometimes even death. It commonly occurs in children younger than 3 years old, as they tend to put objects in their mouth. A local epidemiology study also revealed that among paediatric patients suffering from this condition, 73% were below the age of 3 years. Bronchoscopy is an endoscopic technique of visualizing the inside of the airways for diagnostic and therapeutic purposes. This case reported a 1 years and 3 months old boy with foreign body aspiration. Bronchoscopy with rigid bronchoscope was performed electively. Patient was clinically improved after the bronchoscopy.

Copyright © 2021 Science Midwifery.

1. Introduction

Aspiration of foreign bodies by children can lead to serious illness and sometimes even death. It commonly occurs in children younger than 3 years old, as they tend to put objects in their mouth. A local epidemiology study also revealed that among paediatric patients suffering from this condition, 73% were below the age of 3 years. In this age-group, the risk may also be increased by the immaturity of protective mechanisms in the upper airways.¹ Foreign body aspiration (FBA) is a potentially life-threatening event and is responsible for annually 17.000 emergency room visits in the United States of children under the age of 14. The four most common causes of FBA are peanuts, other food particles, hardware, and pieces of toys. Interestingly, many studies state a higher incidence rate in male than in female children.² Serious acute complications following aspiration of foreign bodies that became gagging in the tracheobronchial tree, including pneumomediastinum, pneumothorax, total atelectasis, foreign body dislodgment, and sometimes need for thoracotomy to overcome this complication. The best method for diagnosing and conveniently for treating FBA is rigid bronchoscopy. In a review of 548 cases of clinically diagnosed FBA, bronchoscopy resulted in a 99% success rate in removing identified foreign objects.^{2,3}

Bronchoscopy is an endoscopic technique of visualizing the inside of the airways for diagnostic and therapeutic purposes. An instrument (bronchoscope) is inserted into the airways, usually through the nose or mouth, or occasionally through a tracheostomy. This allows the practitioner to examine the patient's airways for abnormalities such as foreign bodies, bleeding, tumors, or inflammation. Specimens may be taken from inside the lungs. The construction of bronchoscopes ranges from rigid metal tubes with attached lighting devices to flexible optical fiber instruments with realtime video equipment. The flexible scope initially employed fiberoptic bundles requiring an external light source for illumination. rigid bronchoscopy is still the best solution for the age group concerned. Not only does it ensure the possibility of general anaesthesia and controlled ventilation of a patient during the procedure, but also it limits the risk of complications. Thus, it increases the level of the child's safety, bringing additional comfort to the doctor performing the procedure. The application of a rigid bronchoscope was effective in each and every case, making it possible to extract the major parts of foreign bodies (using forceps) as well as to remove eventual remaining fragments from segmental bronchi (using forceps of a suction terminal).^{4,5} This case report describes the diagnosis and treatment of foreign body aspiration in a 1 years and 3 months old boy.

2. Case Report

A 1 years and 3 months old boy came to the ER of M. Djamil Hospital with breathlessness since 20 hours before admission. He had a history of cough and cold since 1 week before admission. He choked one day before admission while eating peanuts and running. Patient vomitted fraction of peanuts. Breathlessness since 20 hours before admission, no wheezing, not influence by activity

and weather. Patient was referred from Pasaman Barat district Hospital with diagnosis pneumonia aspiration. He had been given fluid maintenance, ceftriaxon 750mg IV, dexametason 1,5mg IV.

Physical examination showed a severely ill and alert. Blood pressure 100/60mmHg with pulse rate 118 times/minute, respiratory rate 56 times/minute, oxygen saturation 91% and body temperature 38°C. Chest examination was normochest and symmetric with epigastrium retraction. Breath sound was vesicular, rhales on both lungs and no wheezing, Cor examination n normal limit, no murmur. Laboratory finding showed hemoglobin 12,3 g/dL, leucocyte 24.240/mm³, and platelet 287.000/mm³. Sodium: 133 mmol/l, Potassium: 5,1 mmol/l, Calcium: 10,2 mg/dl, Random blood glucose: 107 mg/dl. Chest X-ray was performed and no abnormalities was found (Fig 1)

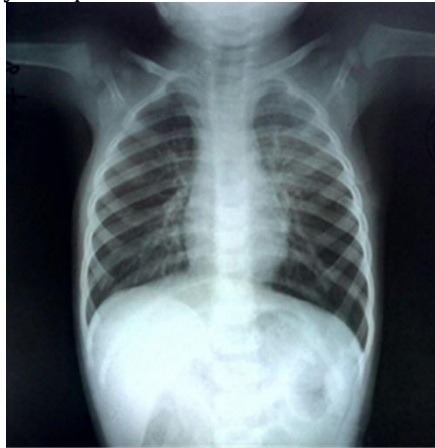

Fig 1. Initial chest x-ray

Patient was admitted with Suspected Pneumonia Aspiration. He was treated O₂ nasal 2 l/minute, IVFD KaEN 1B 12 gtt/minute, Temporary fasting, Dexametason 3 x 1,5 mg iv, Ampicillin 4 x 225 mg iv, Kloramfenikol 4 x 150 mg iv, Paracetamol 4 x 125 mg.

On the first to 5th day of admission, the breathlessness and cough still present. No fever, nausea nor vomiting. Patient was given liquid meal per NGT. Therapy was continued. Repeated chest x-ray showed bronchopneumonia (Fig 2).

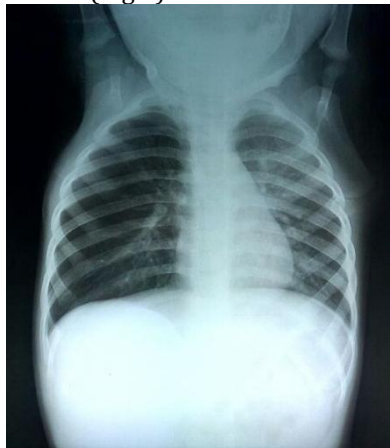

Fig 2. Chest x-ray during admission

On the 6th-8th day, the breathlessness and cough still present, he was consulted to ENT for bronchoscopy. Bronchoscopy was performed and fraction of peanut was found on the left bronchus, extraction of peanuts was carried out (Fig 3, 4 and 5).

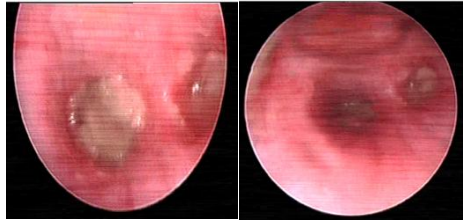


Fig3. fraction of peanuts in the left bronchi are seen through bronchoscopy

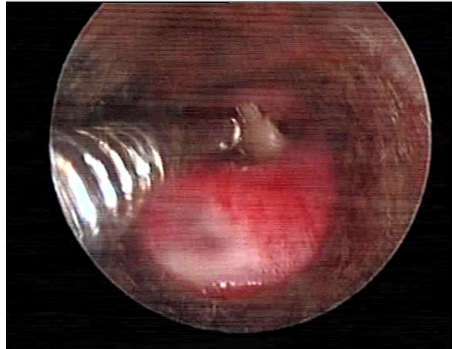


Fig 4. extraction fraction of peanuts with rigid bronchoscopy

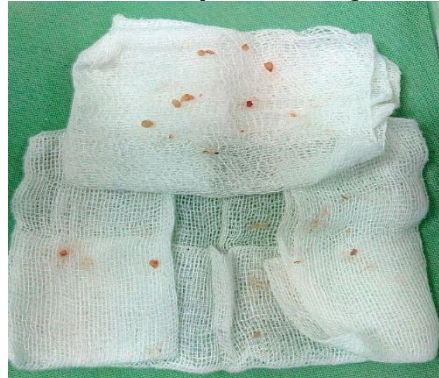

Fig 5. fraction of peanuts in the left bronchus

After the bronchoscopy, patient clinically improved. Chest x-ray was performed after the bronchoscopy (Fig 6). He had no fever nor breathlessness and no chest retraction. He was discharged on the 13th day of admission.

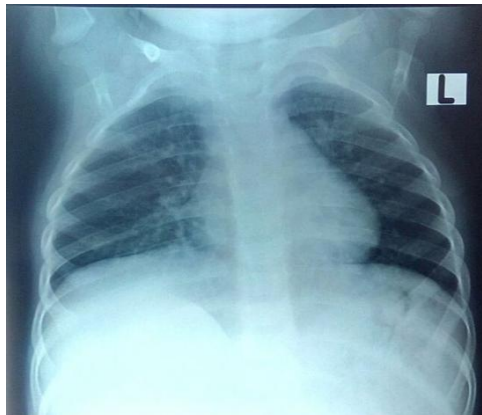


Fig 6. Chest x-ray after bronchoscopy

3. Discussions

We present a case of a 1 years and 3 months old boy with aspiration of foreign bodies (peanuts) at left bronchus. Various literature reported the incidence of foreign body aspiration was 75%-85% in children aged less 15 years old. More than 73% occurs in children less than 3 years. Aspiration of foreign body into the airway is one of the life-threatening conditions in children, especially in children under 3 year and is the cause of sudden death on baby. Several factors affecting the high prevalence of foreign body aspirations in children including children's tendency to put foreign object into their mouth as an attempt to recognize environment, imperfect growth of molar teeth, immature swallowing and protection, and children that oftenly crying, screaming, running or playing with an object inside of their mouth. Lack of parent's awareness and control from parents are causative factor foreign body aspiration in this case.¹

In this case, the foreign body aspirated was peanut. Rovin et al stated that the most foreign body found in children were peanuts (52.3%), food material (12.2%), grains (5.3%), bone (1.5%), plastic (15.1%), metal (4.5%), stone (0.8%), tablets (1.2%) and the rest is none. Yetim also found foreign body aspirations most are peanuts, followed grains, and chicken bones.^{3,6}

The most important data and evaluating suspected foreign body aspiration is an accurate history from parents, but the incident oftenly missed by the adults. Early symptoms in this patient were history of choking followed by coughing and breathlessness. Rovin et al. stated that the initial symptoms of foreign body aspiration were history of choking 85%, paroxysmal coughing 57%, wheezing 57%, and airway blockage 5%. The symptoms also range from asymptomatic phase for 5 days then followed by shortness of breath as a complication phase. Clinical symptoms and complications of object aspiration depend on type, size and where foreign body are located, degree of obstruction of the airway lumen, and interval between aspirations and evaluation.^{6,7} In this patient, his mother reported that the patient was suddenly choking and followed by coughing, vomiting fraction of peanuts, breathlessness and then the patient return to normal.

Symptoms and signs of foreign body aspiration can be seen in three stages; first, acute episodes of choking, followed by hard coughing and breathlessness until complete airway obstruction. Second, asymptomatic episode, when foreign body stucked and breathing reflex are weakening. This phase was varied depending on location, degree of obstruction and local reaction that happened. And the third phase was complicated foreign body in the airway.⁸

In this patient, initial chest x-ray showed no abnormalities was found. Hitter et al found that 80-96% of chest x-ray in FBA was within normal limits. Rovin et al found abnormal chest x-ray in 10-30% of cases. Suspicion of foreign body aspiration usually confirmed with chest x-ray examination. The foreign body in children was usually radiolucent. Radiology examination helps to see indirect sign of the presence of foreign body such as air trapping, pneumonia, collapse, and atelectasis. Hyperinflation obstruction unilateral bronchus is the initial image from lung abnormalities due to aspiration, while pneumonia and atelectasis were found in the late stage. Normal radiology imaging does not exclude the diagnosis foreign body aspiration. Other imaging modalities such as CT scan, MRI and fluoroscopy have limited role in diagnosing foreign body aspiration.¹²

Definitive diagnosis of foreign body aspiration can only be established by bronchoscopy. According to Bopparaju et al⁵, the indications of bronchoscopy are; 1) Patient with history of choking; 2) Patient without a clear history of aspiration, but with physical examination and radiology abnormality; 3) Patient without history of choking, no abnormalities on physical examination and radiology, but with symptoms of coughing, breathlessness, dysphagia and persistent intermittent fever with unclear reasons. Diagnostic bronchoscopy must be performed immediately after any suspicion of foreign body aspiration to avoid complications. Bronchoscopy in this patient was performed using rigid bronchoscope as diagnostics measures and to remove the foreign body. Rigid bronchoscope is the best choice for children, because it can keep airway patency and good visualization. Rigid bronchoscopy is performed with general anesthesia. Diagnostic and therapeutic bronchoscopy needs communication and cooperation between surgeons (operators) and anesthesiologist. Anesthesia with rigid bronchoscope is quite difficult since the anesthesiologist has to divide airway between the operator and to maintain adequate anesthetic, which ventilation with positive pressure is not allowed because it will push foreign body further to distal.^{10,11}

Several studies stated that bronchoscopy can be performed electively to get optimal conditions with experienced operators and anesthesiologists. No increased morbidity was found in elective bronchoscopy for patients with stable conditions. This patient was in stable condition with no emergency symptoms and signs.⁷ So, we consulted to the ENT department and bronchoscopy was done electively to remove FBA.

Several complications during bronchoscopy intra-operatively may occur, caused by trauma and the effect of anesthesia, such as laceration because of the direct pressure on the bronchi, foreign body was pushed further to distal, laryngeal edema, hypoxia, CO₂ retention, laryngospasm, bronchospasm, pneumothorax, and cardiac arrhythmia. We did not find any complication intraoperatively in this patient. The patient had a good clinical improvement after bronchoscopy was performed.

Antibiotics and steroids are very useful in late diagnosis and on organic foreign matter to reduce edema before bronchoscopy. Prophylactic antibiotics may prevent infections that might occur due to foreign body aspiration. Steroids such as dexamethasone or methyl prednisolone was commonly administered in this case.¹² In this patient, antibiotic and steroid were administered which has been known to be useful in reducing edema and inflammation.

4. Conclusion

Early diagnosis and management of foreign body aspiration is important to avoid ineffective management and repetitive treatment. The presence of foreign body in the airway for a long time will cause pneumonia and other irreversible pulmonary parenchymal disease. Proper management and adequate team coordination are necessary to avoid further complications. Normal radiology imaging and stable condition of a child doesn't rule out possible obstruction and interference on breathing.

5. References

- [1] Javier L, Olabbarri M, Domènech A, Rubio B, Yagüe F, Benítez M. Recommendations for the prevention of foreign body aspiration. *An Pediatr (Barc)*. 2017;86:50.e1-e6
- [2] Salih A, Alfaki S, Alam-Elhuda D. Airway foreign bodies: a critical review for a common pediatric emergency. *World J Emerg Med*. 2016;7:5-12
- [3] Yetim T, Bayarogullari H, Arica V, Akcora B, Arica S, Tutanc M. Foreign body aspiration in children; analysis of 42 cases. *J Pulmon Resp Med* 2012;2:1-5
- [4] Becker HD. Bronchoscopy: the past, the present, and the future. *Clin Chest Med*.2010;31:1-18.
- [5] Bopparaju S and Surani S. Evolution bronchoscopy. *Current Respiratory Medicine Reviews*.2014;1:4-10
- [6] Rovin J, Rodgers B. Pediatric Foreign Body Aspiration. *Pediatrics in Review*. 2000;21;86-90
- [7] Dehghani N, ludemann J. Aspirated foreign bodies in children: bc children's hospital emergency room protocol. *C med j*. 2008;50:252-256
- [8] Junizaf M. Foreign body in respiratory tract. In: Soepardi E, Iskandar N, editors. *Ear, nose and throat*. six ed. Jakarta:FKUI. 2003;12:218-223
- [9] Hitter A, Hullo E, Durand C, Righini A. Diagnostic value of various investigations in children with suspected foreign body aspiration Review. *Europ annals of Otorhinolaryngol, Head and Neck dis*. 2011;128:248-252
- [10] Dutau H, Vandemoortele T, Breen DP. Rigid bronchoscopy. *Clin Chest Med*. 2013;34: 427-35.
- [11] Shashidhar K, Roshna R, Nizin S, Nikhil B. Rigid bronchoscopy for foreign body removal: an overview. *Int J otorhinolaryngol head neck surg*. 2017;3:936-938
- [12] Gruber M, Meer G, Ling B, Barber C, Mills N, Neeff M. The bacterial species associated with aspirated foreign bodies in children. *Auris Nasus Larynx*. 2017:1-5