


Comparison of anatomical information of lumbar T2 TSE MRI images with nex variation between use and without sense

Ara Novita Safitri¹, Fani Susanto², Arga Pratama Rahardian³, Pradana Nur Oviyanti⁴, Alan Samudra⁵

^{1,2,3,5}Program Studi Teknologi Radiologi Pencitraan, Fakultas Ilmu Kesehatan, Universitas Muhammadiyah Purwokerto, Indonesia

⁴Departemen Radiologi, Fakultas Kedokteran, Universitas Muhammadiyah Purwokerto, Indonesia

ARTICLE INFO	ABSTRACT
<p><i>Article history:</i></p> <p>Received Apr 9, 2025 Revised Apr 16, 2025 Accepted Apr 25, 2025</p> <hr/> <p><i>Keywords:</i></p> <p>MRI Lumbar NEX Parallel Imaging SENSE</p>	<p>Due to the long scan time, patients often report pain and discomfort during lumbar MRI examination. NEX and SENSE are two parallel imaging parameters that affect scan time. However, the resulting image information is also affected by NEX and SENSE. Therefore, this study examines the information between NEX variations with and without SENSE on anatomical images and their relationship with scan time on lumbar T2 TSE MRI examinations. This study is quantitative and uses an experimental method. The sample in this study was 10 volunteers who would be given 6 treatments, namely NEX 1 variation without SENSE, NEX 1 with SENSE, NEX 2 without SENSE, NEX 2 with SENSE, NEX 3 without SENSE, and NEX 3 with SENSE on Lumbar T2 TSE MRI examinations in January 2025. Using the Visual Grading Analysis (VGA) method, two radiology specialist observers analyzed the image results. Then the Cohen's Kappa consistency test was carried out and the Friedman test was used to verify the questionnaire results statistically. This study shows that there is a significant difference in the value of image information between NEX 1 variations of vertebral body anatomy with and without SENSE. While in the anatomy of the Intervertebral Disc, Ligament, Spinal Cord, and Spinal Stenosis did not show a significant difference in each variation of NEX with and without SENSE. For scan time, with NEX variations using SENSE requires a shorter scan time compared to without the use of SENSE.</p> <p style="text-align: right;"><i>This is an open access article under the CC BY-NC license.</i></p> 

Corresponding Author:

Fani Susanto,
Program Studi Teknologi Radiologi,
Universitas Muhammadiyah Purwokerto,
Jl. KH. Ahmad Dahlan, Dusun III, Dukuhwaluh, Kec. Kembaran, Kabupaten Banyumas, Jawa Tengah, 53182,
Indonesia
Email: fanisusanto@ump.ac.id

INTRODUCTION

Lumbar MRI is often used to assess various disorders, including degeneration of the intervertebral discs that can trigger herniation of the nucleus pulposus (HNP), compression of the thoracic vertebrae, and to view the structure of the spinal cord and cerebrospinal fluid (CSF) and any

abnormalities that may occur (Frost et al. 2019). Lumbar Vertebrae, consists of five bones with a larger part of the neck and spine (thoracic). The appearance of the lumbar vertebrae (corpus) is large, thick, oval, the pedicle is short and thick, the intervertebral foramen is small and the shape resembles a triangle.

The spinous process is thick, wide and somewhat horizontal (1B Anatomy-And-Physiology-For-Paramedicspdf.Pdf, 2011). Various pathological disorders that commonly occur in the Lumbar vertebrae, including scoliosis, fractures, metastasis, ductal stenosis, Lumbar spondylosis, and low back pain (LBP) (Pipit Mulyah, Dyah Aminatun, Sukma Septian Nasution, Tommy Hastomo, Setiana Sri Wahyuni Sitepu 2020).

The radiology modalities that can be used to examine the pathology include mobile x-ray machines, CT-Scans, and MRI (Magnetic Resonance Imaging). A non-invasive method for examining soft tissue that does not require the use of ionizing radiation, magnetic resonance imaging (MRI) is used to monitor treatment and obtain more detailed images (Theodorou et al. 2020)(Peschke et al. 2021). Currently, nuclear magnetic resonance imaging (MRI) is very popular and is routinely performed in hospitals. In general, MRI mode can be used to examine almost any part of the body. Almost 90% of MRI procedures are focused on examining the head and spine, while only about 10% are applied to other organs. Among these examinations, spinal scans tend to be more dominant in medical practice (Lenski et al. 2017).

Lumbar MRI examination is generally used to evaluate abnormalities such as disc degeneration which can cause HNP, thoracic compression, visualization of the spinal cord and cerebrospinal fluid (CSF) and other abnormalities (Nuha et al. 2022). The standard protocol for MRI Lumbar examination to be able to see the anatomical and pathological structures uses the Sagittal T2 TSE, sagittal T1 TSE, sagittal T2 TSE STIR, Axial T2 TSE, and Axial T1 GRE sequences (Khanna, 2015). The routine sequences used for MRI Lumbar examination are sagittal T1 TSE, sagittal T2 TSE, axial T1 TSE, axial T2 TSE (Pipit Mulyah, Dyah Aminatun, Sukma Septian Nasution, Tommy Hastomo, Setiana Sri Wahyuni Sitepu, 2020b). According to Zeitoun et al. (2019) Routine Lumbar MRI protocol consists of sagittal T1, sagittal T2, axial T2.

In general, MRI image quality greatly influences the ability to display the contrast of the body's soft tissues, which depends on factors such as spatial resolution, signal-to-noise ratio (SNR), tissue relaxation time (T1 and T2), and the use of contrast agents that can improve the differentiation of anatomical and pathological structures (Pipit Mulyah, Dyah Aminatun, Sukma Septian Nasution, Tommy Hastomo, Setiana Sri Wahyuni Sitepu, 2020b). Image quality is affected by four elements: CNR, spatial resolution, SNR, and scan time (Agrilian et al. 2023). Scan time, also known as Scane time, is the time required to collect data. The quality of the resulting image can be compromised due to patient movement during the examination, which can be caused by long scan times. Therefore, the value of scan time becomes very important (Ariadi et al. 2023).

MRI scan time is affected by various parameters, one of which is NEX (Number of Excitations), which is the average number of data acquisition repetitions for each signal taken. The higher the NEX value, the more signals are collected, thereby increasing the signal-to-noise ratio (SNR) and producing better quality images. However, increasing NEX also lengthens the scan time. The noise and signal data sets will be stored by K-spase (Diana Ega Rani, 2016). The NEX value can affect the examination time and image quality; higher NEX values result in better images and longer examination times, but lower NEX values result in poorer images (Nirmala 2019).

Research that has been conducted by The Legend of Zelda (2017), said that the use of NEX 2 in lumbar MRI scanning can produce images with optimal quality while maintaining efficient examination duration. Another study conducted by Ariadi et al. (2023), stated that the best NEX value The use of NEX 3 in lumbar MRI examination with sagittal T2 TSE sequence plays a role in increasing the signal-to-noise ratio (SNR), thus producing clearer and more detailed images for anatomical analysis and detection of pathological abnormalities. Meanwhile, research conducted by Agus et al. (2022) stated that use of the NEX 1 resulted in the fastest scan times, although the

potential for reduced image quality due to lower signal-to-noise ratio (SNR) remains a consideration in diagnostic evaluation.

Scan time long periods of time can result in poor image quality and anatomical information, and can also cause patient discomfort during the examination (Fathyan and Rahardian 2024). Time acquisition technique or parallel imaging is one way to reduce examination time. Parallel imaging is a method that can be used to speed up MRI data acquisition (Deshmane et al. 2012). In MRI modality, two methods that are often used for parallel imaging techniques are reconstruction in image space and reconstruction in k-space (Ruel et al. 2004). Parallel Magnetic Resonance Imaging (MRI) examinations have many advantages, including reduced scan time.

First, it is very advantageous for sequences that require short scan times, such as individual breath holds. Second, the total examination time can be shortened, especially in patients who suffer from severe pain in certain situations, such as pain when lying down, in pediatric patients, or in emergency cases (Forshult 2007). Reducing examination time is one way to speed up MRI data acquisition, especially with acquisition techniques or parallel imaging (Deshmane et al. 2012)(Filippi et al. 2012).

In MRI there are several types of parallel imaging (PI), namely GRAPPA (Generically Autocalibrating Partial Parallel Acquisition) on Siemens MRI machines: one of the multi-coil PI methods, ARC (Autocalibrating Reconstruction for Cartesian imaging) on GE MRI machines: one of the multi-coil PI methods, and SENSE (sensitivity encoding) on Philips MRI machines: one of the PI methods used clinically (Indra Wicaksono et al. 2018).

SENSE is a parallel imaging method using images formed from phased array coils. SENSE reconstruction can reduce scan time by accelerating the filling of K-space (Ummah, 2019). Although SENSE image reconstruction takes twice as long as conventional image reconstruction, it can reduce the signal value in anatomical images. The decrease in SNR in SENSE reconstruction affects the reduction factor (R) or the number of elements in the Phased Array coil (Glockner et al. 2005). Depending on the R used, SENSE reduces and speeds up data acquisition (Susanto et al. 2016).

Previous research that has been conducted previously by Wibowo et al. (2015), stated that SENSE can be used for patients with a high level of pain to reduce the possibility of patient movement during the examination with image information without significant differences compared to not using SENSE. While the research conducted by Indrati et al. (2020), stated that the assessment of anatomical information on MRI Lumbar with and without the use of parallel imaging is better using parallel imaging than without using parallel imaging. Another study conducted by 2023 stated that the assessment of anatomical information on MRI Lumbar with and without the use of parallel imaging has differences in some anatomy (Discus Intervetebralis and Corpus Vertebra). Patients often experience discomfort and pain during lumbar MRI examination.

Therefore, the purpose of this study was to determine the best anatomical information on T2 TSE lumbar MRI images with NEX changes between the use of and without SENSE and to determine the differences in anatomical information on T2 TSE lumbar MRI images with NEX changes between the use of and without SENSE.

RESEARCH METHOD

The type of research used is quantitative research with an experimental approach that aims to analyze the differences in lumbar anatomical image information in variations of NEX use with and without SENSE. The study was conducted using a 1.5 Tesla MRI machine at the RSD RSD Gunung Jati Cirebon radiology installation in January 2025. The sample in this study was 10 volunteers who would be given 6 treatments, namely NEX 1 variation without SENSE use, NEX 1 with SENSE use, NEX 2 without SENSE use, NEX 2 with SENSE use, NEX 3 without SENSE use, and NEX 3 with SENSE use in the T2 TSE Lumbar MRI examination.

The results of MRI Lumbar examination images using the T2 TSE sagittal slice sequence in the period of January 2025. The research instruments include MRI machines, Lumbar spine coils, examination equipment (fixation devices, emergency buzzers, headphones, patient clothes, blankets, and pillows), Operator consoles, questionnaires given to 2 radiology specialists to analyze differences in Lumbar anatomical image information in variations in the use of NEX with and without SENSE and analyze artifacts from the sequence.

Two observers (radiology specialists) participated in the qualitative evaluation using Visual Grading Analysis (VGA), which included the vertebral corpus, intervertebral disc, ligaments, spinal cord, and spinal stenosis (Indrati et al. 2020).

:

Table 1. (Tasyawati and Utami 2024) T2 TSE sequence visibility evaluation standard

Anatomy	
Scale	Information
1	Lacking, the image is unclear, not bright enough, blurry, and difficult to analyze.
2	Enough, The image is quite clear, but requires closer inspection.
3	Good, Sharp, bright, clear and easy to analyze image.

The research data were analyzed using the Cohen's Kappa consistency test to evaluate the level of similarity in perception between observers in assessing images, as well as the Friedman difference test to determine the significance of differences in lumbar anatomical image information in various variations of NEX use, both with and without the application of the SENSE technique, in order to obtain optimal images in MRI imaging.

RESULTS AND DISCUSSIONS

The following is a table of volunteer characteristics based on gender in this study.

Table 2. Sample characteristics based on gender

Gender	Amount	Percentage
Man	5	50%
Woman	5	50%
Total	10	100%

The assessment of anatomical image information was carried out by 2 (two) respondents. The research respondents were radiology specialists. The provisions for respondents were that they had expertise in the field of MRI for more than 5 (five) years.

Table 3. Respondents' kapa test results

Variation	Kappa Value	information
NEX 1 without SENSE	0.82	Strong Perceptual Fit
NEX 1 with SENSE	0.78	Strong Perceptual Fit
NEX 2 without SENSE	0.83	Strong Perceptual Fit
NEX 2 with SENSE	0.89	Strong Perceptual Fit
NEX 3 without SENSE	0.80	Strong Perceptual Fit
NEX 3 with SENSE	0.80	Strong Perceptual Fit

In the kappa test, all groups of image information assessed by two observers in the NEX 1 variation with and without SENSE, NEX 2 with and without SENSE, NEX 3 with and without SENSE showed a kappa value above 0.60, which means that the average agreement between the two observers is high. According to Sim and Wright (2005) in Utami (2019), the level of agreement between two observers in classifying subjects can be measured using Cohen's Kappa, with the following categories: <0.00 (Invalid), 0.01-0.20 (Very low), 0.21-0.40 (Low), 0.41-0.60 (Medium),

0.61-0.80 (High), 0.81-1.00 (Very high). Based on these results, there is objective consistency in the six treatments tested.

Data were obtained from the results of image assessment by 2 radiologists by giving a score of 1, 2, and 3 to each image produced by the T2 TSE sequence with variations of NEX 1 without SENSE, NEX 1 with SENSE, NEX 2 without SENSE, NEX 2 with SENSE, NEX 3 without SENSE, and NEX 3 with SENSE. Then the score values of each image from the 2 respondents were summarized and analyzed using SPSS 30 through the Friedman test. The results obtained are as follows.

Table 4. Friedman Test Results between use and no use of SENSE

Variation	p-Value	Information
NEX 1 with and without SENSE	0.001	There is a difference
NEX 2 with and without SENSE	0.001	There is a difference
NEX 3 with and without SENSE	0.007	There is a difference

The results of the Friedman test between NEX 1 with and without SENSE, NEX 2 with and without SENSE, and NEX 3 with and without SENSE obtained a p-Value <0.05. So the null hypothesis (Ho) is rejected, meaning there is a significant difference between images using SENSE and without using SENSE.

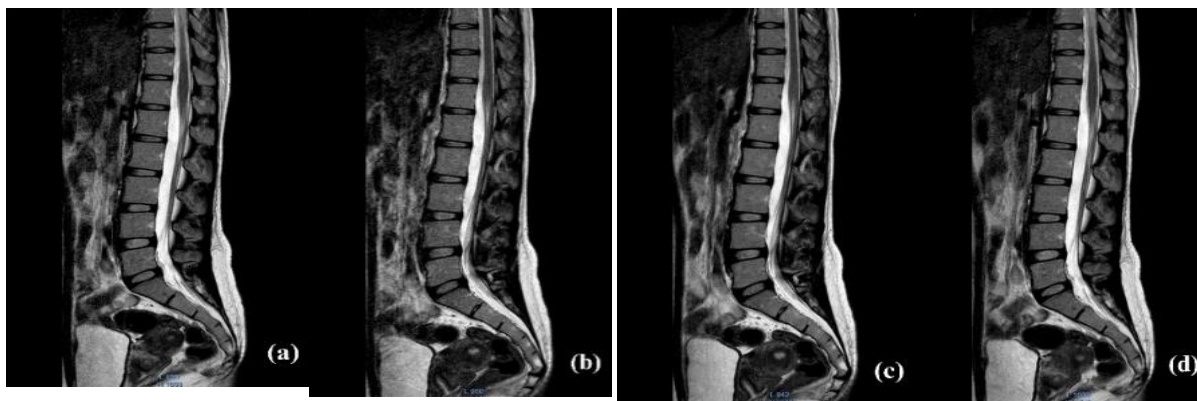
To see which has anatomical image information for the Lumbar, you can look at the mean rank results from the Friedman test between NEX 1 with and without SENSE, NEX 2 with and without SENSE, and NEX 3 with and without SENSE.

Table 5. Mean rank results from the friedman test

Variation	Mean Rank	
	SENSE	NO SENSE
NEX 1	1.31	1.69
NEX 2	1.28	1.72
NEX 3	1.41	1.59

The mean rank results between the NEX 1 variations with and without SENSE, NEX 2 with and without SENSE, and NEX 3 with and without SENSE show that without using SENSE has better image information compared to using SENSE.

To find out in more detail the differences in each anatomy in lumbar MRI, a difference test was carried out using the Friedman test with the results as in Table 6.



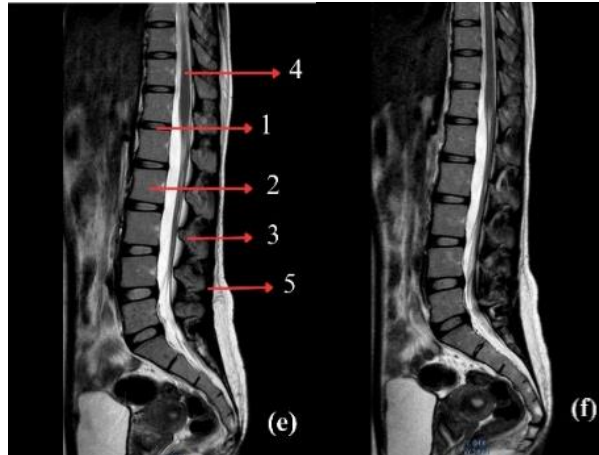


Figure 1. Results of MRI images of the lumbar sagittal section with T2 TSE sequence (a) NEX 1 variation without SENSE, (b) NEX 1 variation with SENSE, (c) NEX 2 variation without SENSE, (d) NEX 2 variation with SENSE, (e) NEX 3 variation without SENSE, and (f) NEX 3 variation with SENSE

Caption figure (e): (1) Corpus Vertebra, (2) Intervertebral Disc, (3) Ligaments, (4) Spinal Cord, (5) Spinal Stenosis

Table 6. Friedman test results of anatomical organ information with NEX variations with and without SENSE

Anatomy	p-Value					
	NEX1		NEX 2		NEX 3	
	with SENSE	without SENSE	with SENSE	without SENSE	with SENSE	without SENSE
Corpus Vertebra	0.025		0.083		0.564	
Intervertebral Disc	0.317		0.317		0.564	
Ligaments	0.083		0.046		0.157	
Spinal Cord	0.317		0.317		0.157	
Spinal Stenosis	0.317		0.317		0.157	

Table 7. Mean rank results of the friedman test per anatomy

Anatomy	Mean Rank					
	NEX 1		NEX 2		NEX 3	
	SENSE	NO SENSE	SENSE	NO SENSE	SENSE	NO SENSE
Corpus Vertebra	1.25	1.75	1.35	1.65	1.45	1.55
Intervertebral Disc	1.45	1.55	1.40	1.60	1.45	1.55
Ligaments	1.35	1.65	1.30	1.70	1.40	1.60
Spinal Cord	1.45	1.55	1.45	1.55	1.40	1.60
Spinal Stenosis	1.45	1.55	1.45	1.55	1.40	1.60

Table 8. Difference in scan time values

Variation	NO SENSE	SENSE
NEX 1	1.18 minutes	52.5 seconds
NEX 2	2.33 minutes	1.43 minutes
NEX 3	3.48 minutes	2.33 minutes

Image quality and information are influenced by four main factors, namely the signal-to-noise ratio (SNR) which determines the clarity of the signal to interference, spatial resolution which affects the sharpness of image details, contrast-to-noise ratio (CNR) which plays a role in distinguishing anatomical structures, and scan time which has an impact on the efficiency of data acquisition and the possibility of motion artifacts (Agrilian et al. 2023). Some parameters that can affect image information and scan time include NEX and parallel imaging SENSE (Diana Ega Rani, 2016). The NEX SNR value is affected; the higher the NEX value, the higher the SNR value and the

clearer the anatomical information. Muthia's (2018) study found that adding or increasing the NEX value would increase the SNR value but reduce the scanning time. The results of this study are in line with these findings. According to the research results Based on the research results of Dwi Rochmayanti et al. (2010), the increase in SNR compared to NEX occurs because NEX acquires and collects more data during the scanning process, thereby improving the quality of the resulting image. Higher SNR is achieved by increasing the recorded signal value above the noise level. This is because the signal amplitude will increase at a larger NEX when data is taken without changing the encoding phase (Diana Ega Rani, 2016).

Enabling SENSE usage will change the SNR value. Reconstruction will cause the SNR value to decrease. SENSE can excite all coils to take images quickly. Therefore, the scanning time becomes shorter, which can decrease the SNR resolution and produce lower image quality (Pipit Mulyah, Dyah Aminatun, Sukma Septian Nasution, Tommy Hastomo, Setiana Sri Wahyuni Sitepu, 2020a). This is in line with research by Apriliani, et al. (2022);2023, because parallel imaging techniques can minimize patient movement during the examination and reduce the duration of the scan, SENSE is very helpful for uncooperative patients. In addition, the use of SENSE parallel imaging techniques can produce images with almost as good quality as images obtained without the technique.

Based on table 6, for the anatomy of the vertebral corpus in the NEX 1 variation with SENSE has a p-value < 0.05 which means there is a difference in image information in the anatomy. Then for the anatomy of the vertebral corpus in the NEX 1 variation without SENSE; NEX 2 with SENSE; NEX 2 without SENSE; NEX 3 with SENSE; NEX 3 without SENSE, the anatomy of the intervertebral disc in the NEX 1 variation with SENSE; NEX 1 without SENSE; NEX 2 with SENSE; NEX 2 without SENSE; NEX 3 with SENSE; NEX 3 without SENSE, the anatomy of the ligament in the NEX 1 variation with SENSE; NEX 1 without SENSE; NEX 2 with SENSE; NEX 2 without SENSE; NEX 3 with SENSE; NEX 3 without SENSE, the anatomy of the spinal cord in the NEX 1 variation with SENSE; NEX 1 without SENSE; NEX 2 with SENSE; NEX 2 without SENSE; NEX 3 with SENSE; NEX 3 without SENSE, and spinal stenosis anatomy in the variations of NEX 1 with SENSE; NEX 1 without SENSE; NEX 2 with SENSE; NEX 2 without SENSE; NEX 3 with SENSE; NEX 3 without SENSE have a p-value > 0.05 which means there is no difference in image information in the anatomy.

These results are in line with previous studies Ariadi et al. (2023), stated that no anatomy was significantly affected by NEX changes. Each anatomy has a different proton density, which results in different signal intensities, which causes variations in the results. Differences can also arise due to the patient or factors that influence the development of noise (Rochmayanti et al. 2010). Based on research data using the SENSE parallel imaging technique, a lower SNR value was obtained compared to without using the SENSE parallel imaging technique, thereby reducing anatomical image information. These results are in accordance with research by (Astari and Semarang 2016) which states that the use of parallel imaging can speed up scanning time but will reduce SNR, which means that anatomical image information is reduced.

For the scan time between the variations of NEX 1 with and without SENSE, NEX 2 with and without SENSE, and NEX 3 with and without SENSE can be seen in table.8 that NEX 1 NON SENSE requires a scan time of 1.18 minutes. NEX 1 SENSE requires a scan time of 52.5 seconds. NEX 2 NON SENSE requires a scan time of 2.33 minutes. NEX 2 SENSE requires a scan time of 1.43 minutes. NEX 3 NON SENSE requires a scan time of 3.48 minutes. And NEX 3 SENSE requires a scan time of 2.33 minutes. So it can be concluded that the use of SENSE can shorten the scan time during the inspection. Because fewer rows are obtained for each section, the scan time becomes shorter. The number of items used in the measurement increases as the scan time decreases (Ummah, 2019).

Scan time is reduced because fewer rows are acquired for each coil element in SENSE, which uses phased array coils to measure and process signals from slices before combining the

components to create an image covering a larger anatomical area. To reduce scan time, the number of coil elements used is proportional. (Indrati et al. 2020).

CONCLUSION

Based on the results of the research that has been done, it can be concluded that the variations of NEX 1, NEX 2, and NEX 3, both with and without SENSE, do not show significant differences in image information. However, scanning with SENS results in a shorter examination time than without SENSE. Therefore, in MRI Lumbar T2 TSE examinations, NEX variations with and without SENSE can be applied in routine examinations, but are more recommended for less cooperative patients to reduce the possibility of motion artifacts due to longer scan durations.

ACKNOWLEDGEMENTS

The author would like to thank the Gunung Jati Cirebon Regional Hospital for granting permission for the initial research stage, the supervising lecturer, and all parties who have contributed to the preparation of this research article.

References

- Agrilian, Meilita Putri, Asumsue Tarigan, Mahfud Edy W, and Gando Sari. 2023. "Penggunaan T2 STIR Dan Fat Saturation Pada Pemeriksaan MRI Lumbal Kasus Hernia Nucleus Pulposus (HNP)." *Jurnal Imejing Diagnostik (JImeD)* 9(1):24-28. doi: 10.31983/jimed.v9i1.9456.
- Agus, Kadek, Cahya Pramana, Ni Putu, Rita Jeniyanthi, I. Bagus, and Gede Dharmawan. 2022. "Magnetic Resonance Imaging: Studi Literature Review." *Jurnal Radiografer Indonesia (JRI)* 5(1):48-53.
- Anon. 2007. "Two Dimensional Parallel Imaging Acceleration With Autocalibrating Reconstruction." *Imaging* 41(9):3345.
- Anon. 2011. "1B Anatomi-Dan-Fisiologi-Untuk-Paramedispdf.Pdf." 66.
- Ariadi, Ilham, I. Putu Eka Juliantara, and Nyoman Supriyani. 2023. "Nautical : Jurnal Ilmiah Multidisiplin Pengaruh Variasi NAQ Terhadap Signal To Noise Ratio (SNR) Pada MRI Lumbal Sekuen Sagittal T2-FSE (Speeder) Dengan Kasus Low Back Pain (LBP)." *Jurnal Ilmiah Multidisiplin : 2829-632X* 1(10):1203-11.
- Brau, Anja. 2007. "New Parallel Imaging Method Enhances Imaging Speed and Accuracy." *Magnetic Resonance in Medicine* 42(5):952-62.
- Citra Latifa, Andi Tenri. 2017. "The Influence of Number of Signal Average Variation to the Scan Time and Anatomic Information of Lumbar MRI on Sagittal Slice with Stir Sequence." *Journal of Medical Science And Clinical Research* 05(06):23146-52. doi: 10.18535/jmscr/v5i6.57.
- Deshmane, Anagha, Vikas Gulani, Mark A. Griswold, and Nicole Seiberlich. 2012. "Parallel MR Imaging." *Journal of Magnetic Resonance Imaging* 36(1):55-72. doi: 10.1002/jmri.23639.
- Diana Ega Rani. 2016. "Optimalisasi Number of Excitation (NEX) Terhadap Signal To-Noise Ratio (SNR) Dan Kecepatan Waktu Scanning Pada Pemeriksaan MRI." *Perpustakaan Airlangga*.
- Fathyan, Azzahra Istna, and Arga Pratama Rahardian. 2024. "Analisis Nilai Signal To Noise Ratio (Snr) Akibat Variasi Nex Pada Pemeriksaan Mri Thoracolumbal Sekuen Sagittal T2 Fat Sat Pada Kasus Low Back Pain (Lbp)." *Jurnal Kesehatan Tambusai* 5(1):1744-52.
- Filippi, Christopher G., Morgan Carlson, Jason M. Johnson, Heather N. Burbank, Gary F. Alsofrom, Trevor Andrews, Filippi Cg, M Carlson, Johnson Jm, and Burbank Hn. 2012. "Improvements in Lumbar Spine MRI at 3 T Using Parallel Transmission." (October):861-67. doi: 10.2214/AJR.11.8139.
- Forshult, Stig E. 2007. *Magnetic Resonance Imaging, MRI - An Overview*.
- Frost, Brody A., Sandra Camarero-Espinosa, and E. Johan Foster. 2019. "Materials for the Spine: Anatomy, Problems, and Solutions." *Materials* 12(2):1-41. doi: 10.3390/ma12020253.
- Glockner, James F., Houchun H. Hu, David W. Stanley, Lisa Angelos, and Kevin King. 2005. "Parallel MR Imaging: A User's Guide." *Radiographics* 25(5):1279-97. doi: 10.1148/rg.255045202.
- Indra Wicaksono, Ary, Emi Murniati, Siti Masrochah, and Poltekkes Kemenkes Semarang. 2018. "Nilai Sensitivity Enchoding (Sense) Pada Sekuen T2 Weighted Balance Turbo Field Echo (Btfe) Pada Pemeriksaan Mrcp Di Instalasi Radiologi Siloam Hospital Surabaya Image Information Value of

- Variation Analysis Value Sensitivity Enchoding (Sense) Using T2 Wei." *JlmeD* 4(2):68-72.
- Indrati, Rini, Iin Saputri Sahlan, Bambang Satoto, and Siti Daryati. 2020. "Perbedaan Kualitas Citra Mri Lumbal Sekuen Tiwi Tse Potongan Sagital Dengan Dan Tanpa Penggunaan Sensitivity Encoding (Sense) Pada Kasus Hernia Nucleus Pulposus." *Jurnal Imejing Diagnostik (JlmeD)* 6(1):16-22. doi: 10.31983/jlmed.v6i1.5560.
- Lenski, Markus, Natalie Büser, and Michael Scherer. 2017. "Concomitant and Previous Osteoporotic Vertebral Fractures." *Acta Orthopaedica* 88(2):192-97. doi: 10.1080/17453674.2016.1273644.
- Nirmala, Fella Ustia. 2019. "The Effect Of Number Of Excitation (Nex) Variation And Blade Technique On T2 Image Quality TSE Sagital Knee MRI." *Jurnal Biosains Pascasarjana* 21(1):32. doi: 10.20473/jbp.v21i1.2019.32-47.
- Nuha, M. D., L. Prasetya, and B. G. Dharmawan. 2022. "Pada Pemeriksaan Mri Lumbal T2Wi Tse Fat Saturation Dan T2Wi Tse Dixon Potongan Sagital Pada Klinis Hernia Nucleus Pulposus Di." *Jurnal Riset Rumpun Ilmu ...* 1(2).
- Peschke, Eva, Patricia Ulloa, Olav Jansen, and Jan Bernd Hoenner. 2021. "Metallic Implants in MRI - Hazards and Imaging Artifacts." *RoFo Fortschritte Auf Dem Gebiet Der Rontgenstrahlen Und Der Bildgebenden Verfahren* 193(11):1285-93. doi: 10.1055/a-1460-8566.
- Pipit Mulyah, Dyah Aminatun, Sukma Septian Nasution, Tommy Hastomo, Setiana Sri Wahyuni Sitepu, Tryana. 2020a. *MRI IN PRACTICE*. Vol. 7.
- Pipit Mulyah, Dyah Aminatun, Sukma Septian Nasution, Tommy Hastomo, Setiana Sri Wahyuni Sitepu, Tryana. 2020b. *MRI TECHNIQUE*. Vol. 7.
- PRASTIWI, ROFIQOH EVI. 2023. "ANALISIS PERBEDAAN KUALITAS CITRA MRI THORACOLUMBAL SEKUEN T2 FSE POTONGAN SAGITTAL ANTARA PENGGUNAAN ARC DAN TANPA PENGGUNAAN ARC PADA KASUS HERNIA NUKLEUS PULPOSUS." *Nucl. Phys.* 13(1):104-16.
- Ruel, Lucile, Pierre Brugières, Alain Luciani, Stéphane Breil, Didier Mathieu, and Alain Rahmouni. 2004. "Comparison of In Vitro and In Vivo MRI of the Spine Using Parallel Imaging." *American Journal of Roentgenology* 182(3):749-55. doi: 10.2214/ajr.182.3.1820749.
- Theodorou, Daphne J., Stavroula J. Theodorou, Sachiko Kakitsubata, Kazuki Nabeshima, and Yousuke Kakitsubata. 2020. "Abnormal Conditions of the Diskovertebral Segment: MRI with Anatomic-Pathologic Correlation." *American Journal of Roentgenology* 214(4):853-61. doi: 10.2214/AJR.19.22081.
- Zeitoun, Rania, and Mohammed Saleh Ali Mohieddin. 2019. "Coronal STIR Sequence, a Simple Adjustment to Routine MRI Protocol for Extra-Spinal Sciatica and Sciatica-like Symptoms." *Egyptian Journal of Radiology and Nuclear Medicine* 50(1):1-9. doi: 10.1186/s43055-019-0096-6.