

Cauda Equina Syndrome

El-Varel Baby Berlianza¹, Rosha Aulia Fadhilah Hafidz²

¹²Universitas Tarumanagara

ARTICLE INFO

Article history:

Received Sep 16, 2022

Revised Oct 02, 2022

Accepted Oct 07, 2022

Keywords:

Cauda Equina Syndrome,
Case Report,
CES

ABSTRACT

Cauda equina syndrome (CES) is a rare condition in which the lumbosacral nerve roots that extend below the spinal cord itself are compressed within the lumbosacral spinal canal. Cauda equina syndrome (CES) is a devastating condition for quality of life which may lead to permanent disability with associated neurological pain affecting the patient, their family and relationships. We hereby present a case regarding 31-year-old man with features of cauda equina syndrome. In this patient MRI was done and revealed degeneration of the lumbar discs, specifically on the L3-4 and L5-S1 segments, which could possibly be preceded by disc herniations (10-12). The spinal cord micturition center is located at S2-S4 levels (anatomically near the L1 vertebrae). Injuries leading to bladder dysfunction may result in detrusor hyperreflexia and detrusor sphincter dyssynergia in suprasacral injuries and detrusor areflexia in sacral injuries. Based on clinical and laboratory examination results, The patient was diagnosed with cauda equina syndrome. Symptomatic measures were then given to the patient, which include codeine 3x10 mg, pregabalin 3x50mg, potassium chloride 2x25 mEq, ketorolac 3x10 mg, and ceftriaxone 1x2 g.

This is an open access article under the [CC BY-NC](#) license.



Corresponding Author:

El-Varel Baby Berlianza,

Universitas Tarumanagara,

Jalan Letjen S. Parman No. 1, Tomang, Grogol petamburan, RT.6/RW.16, Tomang, Indonesia

Email: elvarelbaby@gmail.com, rosshaaulia6@gmail.com

INTRODUCTION

Cauda equina syndrome (CES) is a rare condition in which the lumbosacral nerve roots that extend below the spinal cord itself are compressed within the lumbosacral spinal canal. Usually the cause is a central disc prolapse at the L4/5 or L5/S1 level. More rarely, compression can occur due to pathology in a higher disc or to infection or a tumor (1). Cauda equina syndrome (CES) is a surgical emergency with potentially significant consequences, including bladder, bowel and sexual dysfunction, numbness, weakness, and pain. It is a time-sensitive syndrome, requiring rapid and effective assessment, diagnosis and treatment if the best possible outcome for the patient is to be achieved. MRI is recommended when CES is suspected. (2) Cauda equina syndrome (CES) is a devastating condition for quality of life which may lead to permanent disability with associated neurological pain affecting the patient, their family and relationships. The subsequent effects of this highly disabling disorder can often lead to isolation and despair for patients and their families who may struggle to comprehend the complex and personal issues surrounding this often-invisible

condition (2,3). We hereby present a case regarding a 31-year-old man with features of cauda equina syndrome.

RESEARCH METHOD

We hereby present a case regarding a 31-year-old man with features of cauda equina syndrome. A 31-year-old patient was admitted to Royal Taruma Hospital emergency department on November 22nd, 2021 with back pain specifically on the left side since 3 months ago. The patient has a history of fall 3 months ago from his motorbike. Since one week ago, the pain kept getting worse and radiates to the left extremity, from the thigh down to the foot. Full blood count result was as follow : Hb 12.2 g/dL, Hematocrit 39.9%, leucocyte count 8800 /uL (segmental neutrophil 71%), ESR 7 mm/hour, MCV 62%, MCH 19 pg, MCHC 31 g/dL, platelet count 183000, potassium 3.19 mmol/L, sodium 145 mmol/L. Kidney function test result was as follow : ureum 29mg/dL, creatinine 0.77 mg/dL. The patient's blood glucose level was 142 mg/dL. Chest X-ray revealed thoracal scoliosis (to the right). Lumbar MRI revealed degeneration of L3-L4 and L5-S1 intervertebral discs. The cauda equina is comprised of the second through fifth lumbar nerves, sacral nerves, and coccygeal nerve and begins in the medullary cone (3,4) The incidence of CES varies depending upon the etiology, with an overall prevalence ranging from 1 in 33,000 to 1 in 100,000 persons. Plain radiograph is usually the first study obtained for a patient with complaints related to the spine. MRI is the current study of choice in evaluating patients with suspected CES. In this patient MRI was done and revealed degeneration of the lumbar discs, specifically on the L3-4 and L5-S1 segments, which could possibly be preceded by disc herniations (10-12). The spinal cord micturition center is located at S2-S4 levels (anatomically near the L1 vertebrae). Injuries leading to bladder dysfunction may result in detrusor hyperreflexia and detrusor sphincter dyssynergia in suprasacral injuries and detrusor areflexia in sacral injuries.

RESEARCH RESULTS

Case Presentation

A 31-year-old patient was admitted to Royal Taruma Hospital emergency department on November 22nd, 2021 with back pain specifically on the left side since 3 months ago. The patient has a history of fall 3 months ago from his motorbike. Since one week ago, the pain kept getting worse and radiates to the left extremity, from the thigh down to the foot. The pain worsens if the patient tries to walk and relieved with rest. Since 3 days ago, the patient felt weakness on his left leg, with tingling sensations and numbness. The patient also experienced urinary and fecal incontinence. On physical examination, the patient was fully conscious (GCS 15, E4M6V5), not disoriented, normotensive (130/76mmHg), with normal hear rate (94 bpm) and respiratory rate (20 times per minute), afebrile (37C). The patient weighed 145 kg with 180 cm height and was classified as grade 2 obese, according to the WHO Asia-Pacific BMI classification. General physical examination were within normal limits. Neurological examination revealed normal cranial nerve functions, weakness on the left side of the body (5555/3333), hyporeflexia on the left side of the body with no pathological reflex, and diminished sensoric functions on the left side of the body. Full blood count result was as follow : Hb 12.2 g/dL, Hematocrit 39.9%, leucocyte count 8800 /uL (segmental neutrophil 71%), ESR 7 mm/hour, MCV 62%, MCH 19 pg, MCHC 31 g/dL.

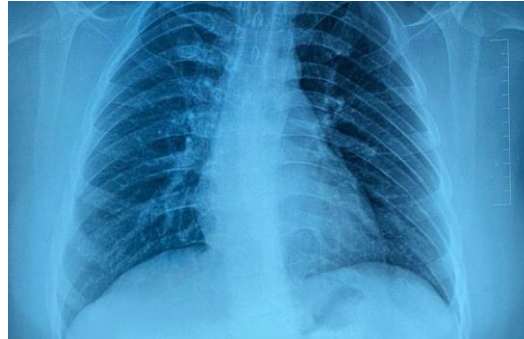


Figure 1. Chest X-ray

Platelet count 183000, potassium 3.19 mmol/L, sodium 145 mmol/L. Kidney function test result was as follow : ureum 29mg/dL,creatinine 0.77 mg/dL. The patient's blood glucose level was 142 mg/dL. Chest X-ray revealed thoracic scoliosis (to the right). Lumbar MRI revealed degeneration of L3-L4 and L5-S1 intervertebral discs.

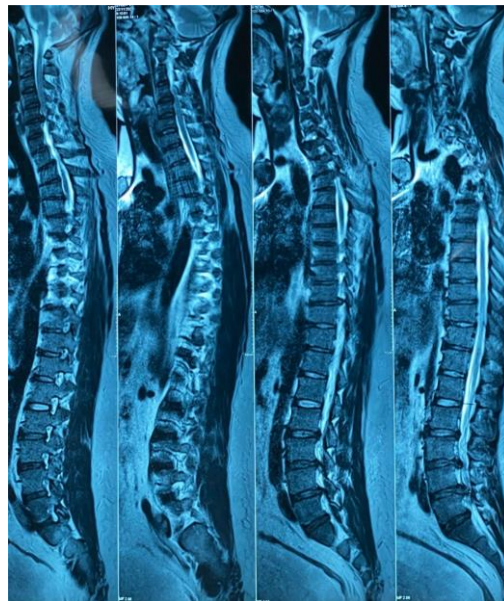


Figure 2. Spine MRI

Based on clinical and laboratory examination results, The patient was diagnosed with cauda equina syndrome. Symptomatic measures were then given to the patient, which include codeine 3x10 mg, pregabalin 3x50mg, potassium chloride 2x25 mEq, ketorolac 3x10 mg, and ceftriaxone 1x2g.

Discussion

Back pain affects up to 75% patients during their lifetime and is a leading cause of disability. While many cases of back pain are relatively benign, cauda equina syndrome (CES) is a potentially devastating cause with the potential for significant morbidity and long-term neurologic deficits. Cauda equina syndrome is a rare but emergent condition associated with back pain and other symptoms resulting from compression of the cauda equina. The cauda equina is comprised of the second through fifth lumbar nerves, sacral nerves, and coccygeal nerve and begins in the medullary cone (3,4) The incidence of CES varies depending upon the etiology, with an overall prevalence

ranging from 1 in 33,000 to 1 in 100,000 persons. While CES can present at any age, most patients with CES are diagnosed around 40 years of age. Additional risk factors include obesity and female gender. (3-5)

CES has multiple etiologies. Trauma is an obvious source. Blunt or direct spinal injury through the cauda equina can cause significant injury. Traumatic injuries of the thoracolumbar spine can result in conus medullaris syndrome (CMS) or cauda equina syndrome (CES). Fifteen percent of spinal cord injuries (SCI) occur in the thoracolumbar spine. In ~ 10–38% of these injuries, the conus medullaris (CM) or cauda equina (CE) is involved; this percentage increases in case of a fracture dislocation. One of the main causes of compression is extruded disc herniation, tumoral lesions, spinal fractures, canal stenosis, infections, post-surgical manipulation, post-spinal anesthesia, ankylosing spondylitis and firearm wounds (6,7). Sacral fractures can also cause CES. Hematomas, abscesses, lymphoma, and other space-occupying lesions that compress nerve roots. Have been described as a cause of CES (8). The patient in this case had a history of trauma and is obese, which are important to be pointed out as risk factors.

The clinical features of CES are usually considered to be a combination of the following occurring in someone with acute or chronic low back pain: disturbance of urinary function, disturbance of saddle sensation, reduced anal tone, and possibly bilateral sciatica. Patients typically present with a classic triad of saddle anesthesia, bowel and/or bladder dysfunction, and lower extremity weakness.(9) Muscle weakness is generally mild, and lower limb weakness associated with CES is predominantly asymmetrical in patients with an incomplete injury (8) , in accordance with the patient in this case.

Plain radiograph is usually the first study obtained for a patient with complaints related to the spine. MRI is the current study of choice in evaluating patients with suspected CES. This modality can be used to evaluate for both extrinsic causes of neural compression (eg, tumors, disc herniation, hematoma, infection) and intrinsic pathology. When an infectious or neoplastic etiology is suspected, administration of intravenous contrast may provide more detail. The disadvantage of MRI is that it is contraindicated in the presence of pace-makers, aneurysm clips, and metal fragments in the eyes or near vital structures. In addition, claustrophobic patients may not tolerate lying in a tube for a prolonged period. Such patients may require sedation, open MRI, or a different imaging modality.

CT with myelography can be used for good visualization of the spinal column. It is an invasive procedure with inherent risks, but it is the study of choice when MRI is contraindicated. CT myelogram provides better evaluation of the osseous structures than MRI does and better evaluation of the spinal cord than plain myelography does. In this patient MRI was done and revealed degeneration of the lumbar discs, specifically on the L3-4 and L5-S1 segments, which could possibly be preceded by disc herniations (10-12).

Bladder studies are occasionally useful in diagnosing CES, but their effectiveness as both diagnostic and prognostic tools has not been definitively established. The spinal cord micturition center is located at S2–S4 levels (anatomically near the L1 vertebrae). Injuries leading to bladder dysfunction may result in detrusor hyperreflexia and detrusor sphincter dyssynergia in suprasacral injuries and detrusor areflexia in sacral injuries.⁴⁷ Postvoid residual bladder volumes may be increased with detrusor areflexia; these may be measured either with a Foley catheter placement or with bladder ultrasound after urination (11).

CES has been classified into incomplete CES (CESI) and complete CES (or CES with true retention; CESR). In CESI, patients present with motor and sensory changes, including saddle anesthesia, but have yet to develop full retention or incontinence of either bowel or bladder. Instead, the visceral changes they undergo are of neurogenic origin, such as straining micturition, possibly using abdominal compression to assist in voiding, loss of urgency, and alteration of urinary sensorium.

In CESR, patients have already developed true retention. Secondary to loss of the visceral neurologic signal to the central nervous system, painless urinary retention, and eventually overflow incontinence, is experienced. Similarly, either retention or incontinence of the bowel may be experienced. Normally, urinary symptoms are recognized secondary to the usually frequent voiding and elimination events.²⁹ This distinction becomes more difficult in the postoperative period in a patient with a Foley catheter. Early recognition of cord compression and immediate decompression has been found to lead to a halt in the progress of neurologic deficits. (6,7,11)

Surgery when it is required must be performed at the earliest opportunity⁽¹²⁾. Conservative treatment alone is rarely indicated because CES is an emergent condition and surgical decompression is the treatment of choice. Decompression for rapidly progressing CES may prevent sphincter paralysis. The best surgical outcomes were reported in patients with the least neurological deficit prior to surgery. Decompression surgery may range between micro discectomy and wide laminectomy with discectomy to limit the manipulation of potentially damaged neural tissue (13,14).

Nevertheless, despite optimal medical care, many patients with CES will suffer long-term symptoms with significant disability. It is vital to recognize that even after surgery patients will often not have normal return of bladder and/or bowel function. In addition, they may have altered sensation in their limbs leading them prone to pressure ulceration. They will have been going through a very significant and traumatic life event and will be extremely frightened regarding the future. Consequently, patients postoperatively who have residual symptoms should be referred to a rehabilitation consultant. It is crucial in the early postoperative period that proper attention is paid to bladder residual volumes. The bladder is vulnerable to stretching and subsequently infections which must be prevented by proper catheterization techniques. It may be necessary to teach the patient the technique of intermittent self-catheterization to allow return to home. Approximately 75% of all CES patients will eventually have acceptable urological function, though frequently with chronic back pain and some motor and sensory deficits in the perineum and lower limbs (1,15).

CONCLUSION

We reported a case of a 31-year-old male with a history of motor vehicle accident and symptoms of CES which are saddle anesthesia, unilateral limb weakness and fecal and urinary incontinence. MRI imaging revealed degeneration of L3-L4 and L5-S1 discs, which supports the clinical diagnosis of CES.

References

- [1.] Barraclough K. Cauda equina syndrome. *BMJ*. 2021;372(32):1-5.
- [2.] Rider LS, Marra EM. Cauda equina and conus medullaris syndrome. *StatPearls*. 2021.
- [3.] Hoeritzauer I, Wood M, Copley PC, Demetriades AK. What is the incidence of cauda equina syndrome? A systematic Review. *Journal of Neurosurgery : Spine SPI*. 2020;32(6):823-41.
- [4.] Long B, Koyfman A. Evaluation and management of cauda equina syndrome in the emergency department. *American Journal of Emergency Medicine*. 2019.
- [5.] Brouwers E, Meent H, Curt A, Starremans B, Hosman J, Bartels R. Definitions of traumatic conus medullaris and cauda equina syndrome: a systematic literature review. *Spinal Cord*. 2017;55:886-90
- [6.] Fuso FA, Dias L, Letaif OB, Cristante AF. Epidemiological study of cauda equina syndrome. *Acta Ortop Bras*. 2013;21(3):159-62.
- [7.] Gitelman A, Hishmeh S, Morelli BN. Cauda Equina Syndrome: A Comprehensive Review. *Am J Orthop*. 2018;37(12):566-72.
- [8.] Shi J, Jia L, Shi G, Wang B, Wu J. Clinical classification of cauda equina syndrome for proper treatment. *Acta Orthopaedica*. 2020;81(3):391-5.
- [9.] Hur J, Park D, Lee J, Cho T, Park J. Guidelines for cauda equina syndrome management. *J Neurointensive Care*. 2019;2(1):14-6.
- [10.] Deninz K, Pararajasingham J. Cauda Equina Syndrome. *InnovAiT*. 2021.

- [11] Uckun OM, Algaoz F, Polat O, Divangolu D, Dahoglu E, Belen A et al. Urgent operation improves weakness in cauda. Equina syndrome due to lumbar disc herniation. *Turk J Phys Med. Rehad.* 2019;65(3):222-7.
- [12] Eadmee N. Cauda equina syndrome. : principles of management. *Orthopaedics and Trauma.* 2020;34(5):248-54.
- [13] Washington State Department. Medical Treatment Guidelines : Work-Related Acute Cauda Equina Syndrome (CES). 2016.
- [14] Foruiri X, Gopeguiio K, Sanches G, Aguirre U. Cauda equina syndrome secondary to lumbar disc herniation: surgical delay and its relationship with prognosis. *Rev Esp Cir Ortop Traumatol.* 2016;60(3):153-9.
- [15] Rezvani M, Mohamadhoseini E, Rastgoo A, Kamangar M, Noorian M. Prognosis. Of cauda equina syndrome caused by herniated risk. After lumbar disk operation. *IRNS.* 2018;4(12):12-7.